

# TEMPORAL HEMODYNAMIC AND HISTOLOGICAL CHANGES IN A RAT MODEL OF SUGEN-INDUCED PAH



V. GIROD, A. BOURDET, A. BOUZEREAU, D. REVY, S. ROBELET  
 SYNCROSOME, Luminy biotech entreprises, Marseille, France

## AIMS

Pulmonary arterial hypertension (PAH) is a rare cardiopulmonary disorder characterized by progressive obliteration of small pulmonary arterioles that leads to increased pulmonary vascular resistance. Because of impaired blood flow in pulmonary arteries, right ventricular pressure (RVSP) rises, ultimately leading to right ventricular failure and premature death. This disorder is characterized by an imbalance in the production of endothelium-derived vasodilator and constrictor factors, dysfunctions of pulmonary endothelial cells (EC) and the proliferation of smooth muscle cells (SMC). Considerable progress has been made in the understanding of the mechanisms underlying PAH and a number of new drugs have been recently approved. However, these drugs do not cure PAH and are often associated with significant adverse effects. More research is needed to develop new therapeutic strategies and this requires both the improvement of existing animal models and the development of more predictive models.

The most commonly used animal models are rodents exposed to hypoxia or treated with monocrotaline (MCT). These "classic" models provided great insight into the mechanisms responsible for the development of PAH, but they do not perfectly model the changes occurring within the small pulmonary arteries.

Vascular remodeling in small pulmonary arteries is indeed an important feature of PAH and includes medial hypertrophy, intimal proliferation, fibrotic changes and the appearance of plexiform lesions. While such changes cannot usually be observed in MCT- and hypoxia-induced PAH animal models, exposure of animals to SUGEN+hypoxia+normoxia lead to a complex vascular remodeling concomitant with an increase in RVSP and a right ventricular (RV) hypertrophy. The present work aimed at characterizing the temporal hemodynamic and histological changes occurring in animals exposed to SUGEN+hypoxia+normoxia and to test the efficacy of reference drugs.

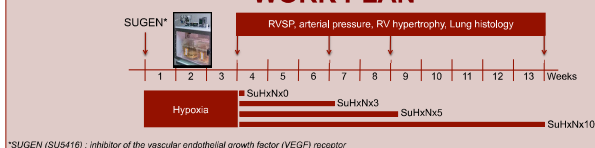
## METHODS

The experimental procedures were carried out in accordance to European guidelines for the care and use of laboratory animals (Directive 2010/63/UE). Every effort was done to minimize animal suffering and reduce the number of animals used in the experiments. The animals, which were included in these experiments, were naïve to previous administration of drugs.

PAH was induced by injecting male Sprague Dawley rats once with SUGEN (SU5416, 20 mg/kg, S.C.) on Day 0. Animals were then exposed to normobaric hypoxia (10 ± 1%) for three weeks before returning or not (group SuHxNx0) to normoxia for three (SuHxNx3), five (SuHxNx5) or 10 additional weeks (SuHxNx10). Additional animals exposed to SuHxNx3 were treated from D22 to D42 with an endothelin receptor antagonist (ERA, Macitentan 10 and 30 mg/kg, P.O.) or with a phosphodiesterase type 5 inhibitor (PDE<sub>5</sub> inhibitor, Tadalafil 40 mg/kg, P.O.).

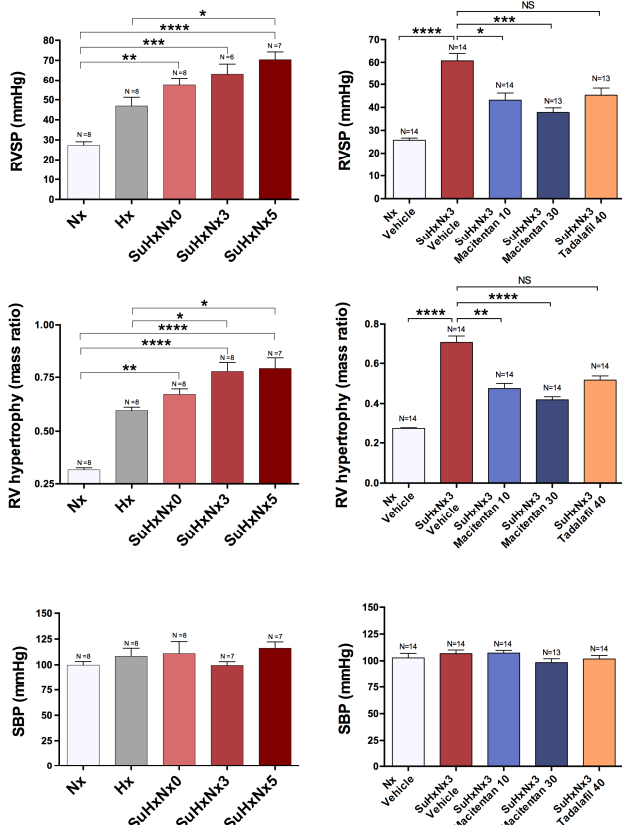
At the end of the protocol, both RVSP and systolic pressure were recorded and heart was collected in order to evaluate RV hypertrophy (Fulton index). Lungs were also collected and processed for histological assessment. Fifty small pulmonary arteries (external diameter < 100 µm) were scored according to Heath-Edward's grading system and classified as "opened" or "partially or completely occluded".

## WORK PLAN

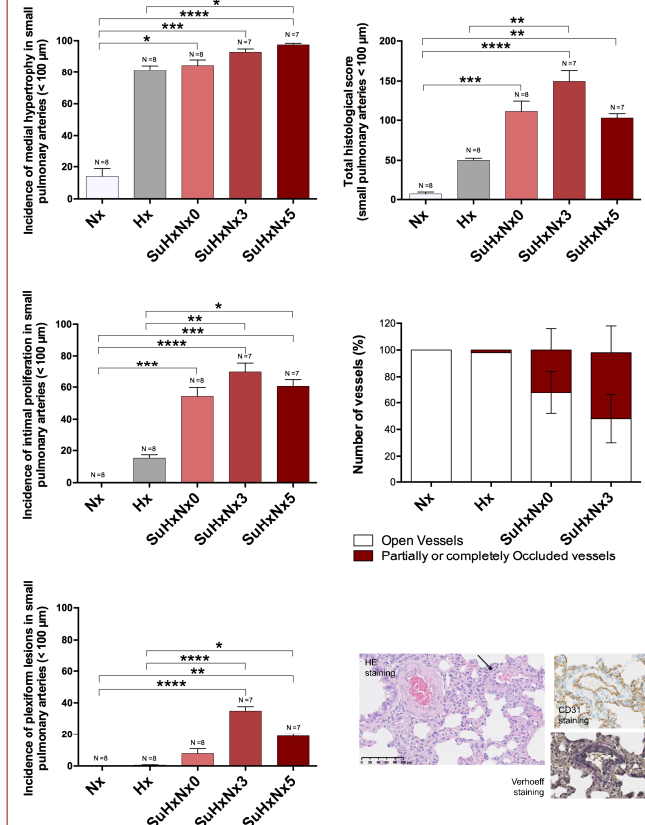


## RESULTS

### HEMODYNAMIC / RV HYPERTROPHY



### HISTOLOGY



Differences between groups were assessed using a Kruskal-Wallis test followed by Dunn's multiple comparisons test. The number (Ntx) above each bar indicates the number of animals included in the analysis. A value of p < 0.05 was considered statistically significant. \*p<0.05; \*\*p<0.01; \*\*\*p<0.001; \*\*\*\*p<0.0001.

## CONCLUSIONS

- Treatment with SUGEN associated with an exposure to hypoxia induces a rise in RVSP concomitant with the development of a clear RV hypertrophy.
- Unlike hypoxia alone, treatment with SUGEN in combination with hypoxia+normoxia induces a complex remodeling and the occlusion of small pulmonary arteries.
- In animals treated with SUGEN, intimal proliferation, fibrosis and plexiform lesions are observed soon after the end of hypoxia and got worse after 3 weeks of normoxia.
- Increasing the duration of normoxia worsens the disease as evidenced by the increase in RVSP, RV hypertrophy and the extend of vascular remodeling. Death rate rises when increasing the duration of normoxia up to 10 weeks.
- Chronic treatment with the dual endothelin receptor antagonist Macitentan demonstrates clear and dose-dependant beneficial effects on RVSP and RV hypertrophy.
- Tadalafil, a PDE<sub>5</sub> inhibitor, tends to antagonize SUGEN-induced rise in RVSP and RV hypertrophy without reaching statistical significance.

→ Taken together, these results strongly support the use of SuHxNx3 protocol as a predictive and reliable model for the preclinical evaluation of new drug candidates for the treatment of human PAH.<sup>^</sup>